

Gastroschisis Repair Technique using Autologous Umbilical Cord Flap in a Resource Limited Setup: Case Series

DILEEP GARG¹, VINAY MATHUR², UMESH BAHADUR SINGH³, JITENDRA GROVER⁴

ABSTRACT

The commonly used surgical methods of gastroschisis repair are operative fascial closure (primary closure), silo application (staged closure), or sutureless closure technique, adapted accordingly to different scenario. This case series presents an initial experience of gastroschisis repair method with an under-reported surgical technique that can be adapted for the repair of gastroschisis in a resource limited setup. The umbilical flap cover is a reasonable method, seems to have favourable results that can render an autograft like covering to exposed visceral organs. This method does not increase the intra-abdominal pressure and also providing a better compliant environment for the growth of the abdominal space. Eight cases have been managed with this technique during the last 4 to 5 years, out of which seven are under follow-up, with age ranging from two months to four years. Umbilical flap harvested from the native umbilical cord is a readily available autologous tissue with an abundance of Wharton's jelly and stem cells.

Keywords: Abdominal wall defect, Umbilical patch, Wharton's jelly

INTRODUCTION

Gastroschisis is a well-known congenital abdominal wall defect with an estimated incidence of 1:2,000-3,000 newborn and now often diagnosed by antenatal fetal ultrasound [1]. The entity is characterised by a defect of the anterior abdominal wall with extrusion of abdominal viscera. This case series consisted of eight children on whom the gastroschisis repair technique using autologous umbilical cord flap was done. This is an under-reported technique and to date a few case reports exist. The authors experienced a good surgical outcome at the tertiary care centre using this technique, during last 4 to 5 years.

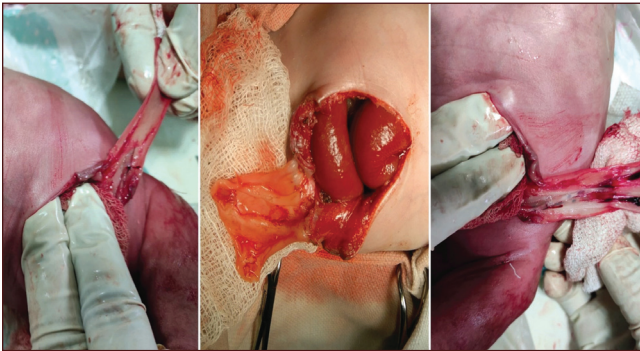
CASE SERIES

These eight patients reported to the unit of Paediatric Surgery at the tertiary health centre within the last 4 to 5 years. Retrospectively, details of all the cases were obtained from the medical records. There were seven patients of survival and one death occurred. All eight cases of gastroschisis were inborn, antenatal detected and selection for umbilical graft repair was arbitrary or surgeon's choice. The average gestational age was 38 weeks. The average birth weight was 2.5 kg. No other gross congenital anomaly was recorded in all eight cases.

At the time of delivery, the exposed viscera were received in a sterile polybag along with an intact umbilical cord having some longer length than usual. The patients were shifted to Neonatal

Intensive Care Unit (NICU) for resuscitation and were intervened in NICU using local anaesthesia, analgesia, minimal surgical intervention was done within 2 to 4 hours of birth to prevent further environmental exposure and gut oedema. As per the hospital protocol, under aseptic precautions, the contents were reduced into the abdominal cavity with gentle manipulation of bowel loops. A small amount of injection Xylocaine 2% with Adrenaline (1:200,000) was infiltrated along with the umbilical ring or umbilicus-skin junction and margins of abdominal wall defect using 26G needle syringe. The umbilical cord stump was opened lengthwise till the umbilical ring without detaching from the skin to spread in a flap manner [Table/Fig-1]. Intraoperative bowel decompression was done by gentle pressure on the bowel to evacuate meconium per rectal. The umbilical flap was sutured to margins of the defect to cover the remaining exposed viscera. It ensured a pressure-free and gap-free closure having medicated paraffin coated dressing to keep the surface moist and aseptic.

The summarised medical record of all eight cases of gastroschisis has been given in [Table/Fig-2] and follow-up pictures are given in [Table/Fig-3]. The average interval of delivery to surgical intervention was three hours. The average duration of the surgical procedure was 20 minutes. In the same NICU, for all patients in the postoperative period, daily dressing was done using a medicated paraffin sheet, until granulation tissue and epithelisation appeared and replaced the umbilical graft. The



[Table/Fig-1]: Intraoperative umbilical cord flap-the umbilical stump opened longitudinally till umbilical skin junction, without detaching from the skin and spread or trimmed according to the size of deficiency.

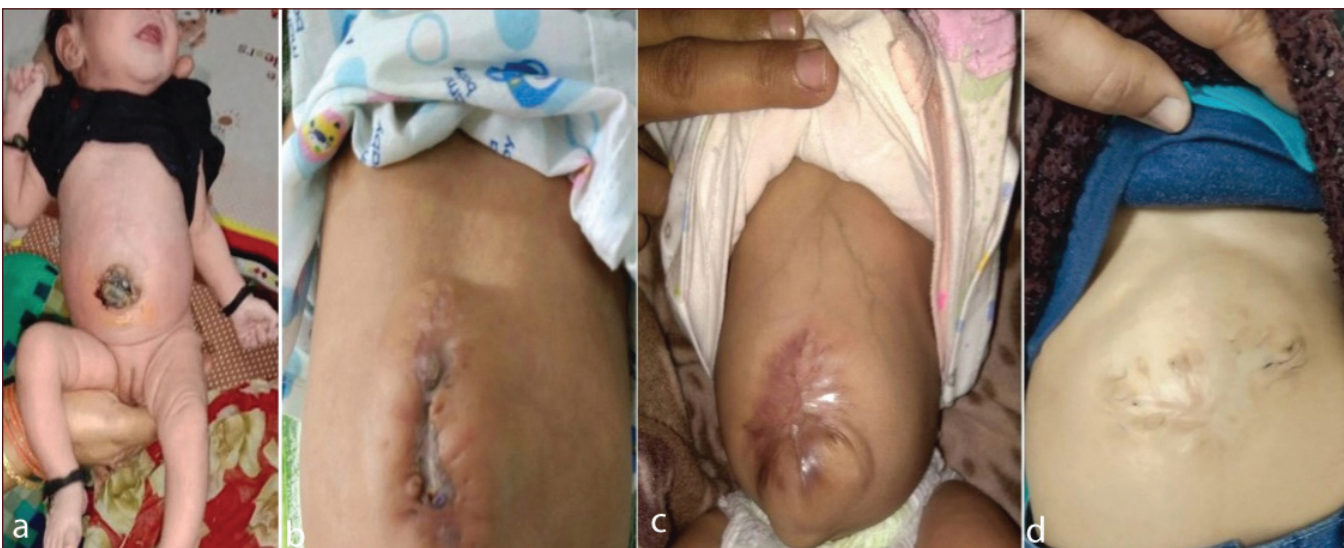average duration of wound epithelisation was 21 days among the survived cases. The Nasogastric (NG) tube was kept in the postoperative period till aspirates minimised. The NG tube aspirate was cleared at an average day six of surgery and the patients passed stools at an average of day eight of surgery.

Initial small feeds were started with expressed breast milk given via NG tube for 4 to 6 days until good suckling developed for adequate breastfeeding. The average duration of tolerating feed was 11 days among survived cases. Within four weeks, the graft was fully epithelised and covered with skin having an underlying large ventral hernia. All survived patients are thriving well and gained weight at follow-up. The ventral hernia repair was planned for a later age.

One child died of Necrotising enterocolitis and gut perforation on the ninth postoperative day. The apparent causative factor was prematurity and septicaemia. Regarding other complications, two out of eight patients encountered septicaemia and two complicated by electrolyte abnormality. Septicaemia was managed with intravenous antibiotics, according to blood culture and sensitivity. Regarding electrolyte abnormality, one patient was detected with hyponatremia and another with hypocalcaemia. Both were managed with justified fluid therapy.

Serial no.	Gestational age at birth (weeks)	Weight (kg)	Procedure done at postnatal (hours)	Average procedure duration (minutes)	Time to establish NG feed (days)	Complications	Outcome
1	39	2.6	3	16	11	Hypocalcaemia	Survived
2	40	2.7	4	18	10	None	Survived
3	41	2.8	2	20	10	None	Survived
4	41	2.7	3	18	12	none	Survived
5	35	2.6	4	22	13	Septicaemia	Survived
6	34	2.2	2	24	10	Septicaemia	Survived
7	34	2.4	3	22	11	Hyponatremia	Survived
8	32	2.0	3	20	-	NEC causing Gut perforation	Died

[Table/Fig-2]: Summary of cases.



[Table/Fig-3]: Follow-up pictures of different patients at: a) one month; b) six months; c) One year; d) Three years.

DISCUSSION

The surgical principle behind gastroschisis closure or repair is to provide a tissue cover to prevent further visceral injury caused by environmental exposure and simultaneously dealing with abdominal compartment syndrome. A high survival rate has been noted in rich-resource settings, with contemporary studies showing survival rates up to 90% in high-income countries compared to low-income countries [2]. There is also hidden mortality in patients who may never seek medical attention or are referred to a tertiary care centre due to the perceived dismal survival in some resource-limited or low-income countries [2].

The principal surgical management of gastroschisis is the closure of defect to cover the exposed viscera either by primary repair or by staged repair. The most frequent approach reported by many centers is staged repair by applying silo bag and repair of defect once the viscera are well within the peritoneal domain. Once closed either by primary or by staged repair, the main problem encountered in the postoperative period is to prevent increased intra-abdominal pressure. Alongside while using the silo reduction technique, it is difficult to maintain an aseptic environment inside the peritoneal cavity during the gradual silo reduction process.

The most common methods exercised are an operative fascial closure with sutures and a flap closure [3]. In case of inability to close the defect by primary closure due to inadequate volume of the peritoneal cavity, a preformed silo pouch or a sterile polybag pouch is applied to cover the exposed abdominal contents. The silo is tightened to achieve a progressive reduction of viscera into the abdominal cavity until abdominal closure is achieved in the operating room. The primary closure or single-stage closure techniques have shown a high rate of mortality and morbidity [4] or equivocal results compared to staged closure [5]. The main factors that seem to play the role in those complications were the increased intra-abdominal pressure causing compartment syndrome and the increased duration of surgery.

The silo bag technique showed more favourable results than primary closure [4]. Nevertheless, in this technique, some different factors prompt complications like fluid loss and electrolyte disturbances due to leakage of peritoneal fluid. Sometimes intra-peritoneal sepsis causes life-threatening complications and prolonged recovery of bowel functions. The postoperative management of the silo bag is a little tedious. It needs daily progressive tightening of the bag, leading to a forceful reduction of bowel into the peritoneal cavity, which may sometimes cause increased intra-abdominal pressure.

In 2004, the sutureless closure of the gastroschisis abdominal wall defect was popularised by Sandler A et al., [6]. This technique utilises the remnant umbilical cord to close the abdominal wall

deficiency. The umbilical cord was contained in place with an overlying transparent medical dressing. The sutureless closure technique has the intended benefits of lower intra-abdominal pressure after closure, confined time under mechanical ventilation, and enhanced cosmetic outcomes. After its inception, the sutureless approach embraced in multiple centers and various studies were conducted to compare the sutured and sutureless closure techniques. About the present authors' experience with this technique, the main difficulty encountered during the reduction of bowel loops into the peritoneal cavity was the inadequate size of the abdominal domain, especially in large size defects. Subsequently, if a forceful reduction was performed, then a high chance of respiratory compromise and increased intra-abdominal pressure was inevitable. But at centers like the present one, having limited resources, lacking well-equipped NICU and neonatal anaesthesia, the authors observed good feasibility of umbilical flap technique. This technique does not mandate neonatal anaesthesia and seems to hold more advantages compared to a sutureless closure technique, like, no increase in intra-abdominal pressure, easy reduction of viscera back into the peritoneal cavity irrespective of sizes or severity of gastroschisis defect [6,7].

Zivkovic SM first reported the technique of umbilical patch repair for large size defects to neutralise the effect of raised intra-abdominal pressure [8]. Despite being a very expedient gastroschisis repair technique, this technique has been under-reported and limited to few case reports only. Gharib M et al., described the application of amnion picked from the placenta to repair the large size defects [9]. The autologous fresh umbilical cord flap is supposed to have umbilical amnion cover with Wharton's jelly having an abundance of germ cells [10]. There is no issue of availability or external material use like a silo bag. The natural cover to the exposed bowel loops provides a favourable and sterile environment to remodeling of thickened and oedematous bowel loops, helping in regaining the early function of the bowel. This technique seems to encompass the merits of both popular repair techniques, silo closure, and sutureless umbilical closure. In this innovative technique, gentle viscera reduction is accomplished with a widening of the defect until a pressure-free reduction obtained. The post reduction deficiency is covered by umbilical flap without any tightness on the suture line which considerably decreases the chances of intra-abdominal compartment syndrome and additional related complications. This tissue was chosen because it is an indigenous, autologous and non immunogenic membrane having Wharton's jelly bearing plentiful stem cells. Although the authors have managed only eight such cases so far, review of postoperative outcomes seem to have better outcomes utilising umbilical cord flap though, proper case-control study mandate to insist on its superiority. Some studies have shown that the amnion flap closure gives a better outcome than the

classical silo closure or primary repair [10,11]. The limitation of this technique is the requirement of ventral hernia repair surgery at a later age. However, in many cases managed by skin flap primary closure or silo staged repair, also requires ventral hernia repair at a later age.

CONCLUSION(S)

The native umbilical patch cover containing Wharton's jelly and amnion can provide a good and easily accessible cover for large size defects of gastroschisis in resource limiting conditions.

Acknowledgment

We are thankful to continuous support and guidance of our head of department, Dr Manoj Joshi for his encouragement towards further study of innovative surgical techniques.

REFERENCES

- [1] Lepigeon K, Van Mieghem T, Vasseur Maurer S, Giannoni E, Baud D. Gastroschisis-what should be told to parents? *Prenat Diagn.* 2014;34(4):316-26. Review.
- [2] Miranda ME, Emil S, Paixão RM, Piçarro C, Cruzeiro PCF, Campos BA, et al. A 25-year study of gastroschisis outcomes in a middle-income country. *J Pediatr Surg.* 2019;54(7):1481-86.
- [3] Youssef F, Gorgy A, Arbash G, Puligandla PS, Baird RJ. Flap versus fascial closure for gastroschisis: A systematic review and meta-analysis. *J Pediatr Surg.* 2016;51:718-25.
- [4] Kunz SN, Tieder JS, Whitlock K, Jackson JC, Avansino JR. Primary fascial closure versus staged closure with silo in patients with gastroschisis: A meta-analysis. *J Pediatr Surg.* 2013;48:845-57.
- [5] Poola AS, Aguayo P, Fraser JD, Hendrickson RJ, Weaver KL, Gonzalez KW, et al. Primary closure versus bedside silo and delayed closure for gastroschisis: A truncated prospective randomized trial. *Eur J Pediatr Surg.* 2019;29:203-08.
- [6] Sandler A, Lawrence J, Meehan J, Phearman L, Soper R. A "plastic" sutureless abdominal wall closure in gastroschisis. *J Pediatr Surg.* 2004;39(5):738-41.
- [7] Bianchi A, Dickson AP. Elective delayed reduction and no anaesthesia: 'minimal intervention management' for gastroschisis. *J Pediatr Surg.* 1998;33(9):1338-40.
- [8] Zivkovic SM. Repair of gastroschisis using umbilical cord as a patch. *J Pediatr Surg.* 1991;26:1179-e80.
- [9] Gharib M, Ure BM, Klose M. Use of amniotic grafts in the repair of gastroschisis. *Pediatr Surg Int.* 1996;11:96-99.
- [10] Zivkovic SM, Djordjevic M, Milic N, Smoljanic Z, Djuricic G, Pavicevic P, et al. Effectiveness of Wharton's jelly stem cells in gastroschisis repair using the inner surface of the umbilical cord as a patch: long-term results. *Ann Pediatr Surg.* 2015;11(3):173-80.
- [11] Alejandro JHR. Umbilical cord patch versus conventional primary closure in gastroschisis and omphalocele. *Res Pediatr Neonatol.* 2018;2(3):155-62.

PARTICULARS OF CONTRIBUTORS:

1. Associate Professor, Department of Paediatric Surgery, G R Medical College, Gwalior, Madhya Pradesh, India.
2. Associate Professor, Department of Paediatric Surgery, G R Medical College, Gwalior, Madhya Pradesh, India.
3. Assistant Professor, Department of Paediatric Surgery, G R Medical College, Gwalior, Madhya Pradesh, India.
4. Assistant Professor, Department of Paediatric Surgery, G R Medical College, Gwalior, Madhya Pradesh, India.

NAME, ADDRESS, E-MAIL ID OF THE CORRESPONDING AUTHOR:

Jitendra Grover,
E 206, DB City, Gwalior, Madhya Pradesh, India.
E-mail: jitendra.grover2@gmail.com

PLAGIARISM CHECKING METHODS: ^[Jain H et al.]

- Plagiarism X-checker: Apr 25, 2020
- Manual Googling: Jul 07, 2020
- iThenticate Software: Sep 15, 2020 (15%)

ETYMOLOGY: Author Origin

AUTHOR DECLARATION:

- Financial or Other Competing Interests: None
- Was Ethics Committee Approval obtained for this study? No
- Was informed consent obtained from the subjects involved in the study? Yes
- For any images presented appropriate consent has been obtained from the subjects. Yes

Date of Submission: **Apr 24, 2020**
Date of Peer Review: **May 12, 2020**
Date of Acceptance: **Jul 10, 2020**
Date of Publishing: **Sep 30, 2020**